CT Scans

Definition

Computed tomography (CT) scans are completed with the use of a 360-degree x-ray beam and computer production of images. These scans allow for cross-sectional views of body organs and tissues.

Comment [1]: A CT scan uses x-ray scans and an MRI scan uses magnets

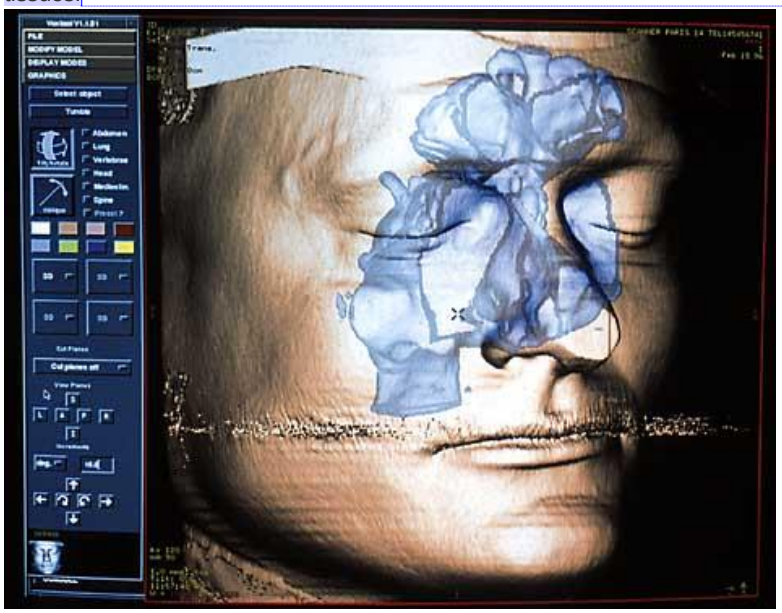

CT scan of facial sinuses.
Pascal Goetgheluck/Photo Researchers, Inc.

Colorized CT scan of human abdomen—aorta is dead center in red.
SPL/Photo Researchers, Inc.

Purpose

CT scans are used to image a wide variety of body structures and internal organs. Since the 1990s, CT equipment has become more affordable and available. In some diagnoses, CT scans have become the first imaging exam of choice. Because the computerized image is so sharp, focused, and three-dimensional, many tissues can be better differentiated than on standard x rays. Common CT indications include:

- Sinus studies. The CT scan can show details of a sinusitis, and bone fractures. Physicians may order CT of the sinuses to provide an accurate map for surgery.
- Brain studies. Brain scans can detect hematomas, tumors, and strokes. The introduction of CT scanning, especially spiral CT, has helped reduce the need for more invasive procedures such as cerebral angiography.
- Body scans. CT scans of the body will often be used to observe abdominal organs, such as the liver, kidneys, adrenal glands, spleen, and lymph nodes, and extremities.
- Aorta scans. CT scans can focus on the thoracic or abdominal aorta to locate aneurysms and other possible aortic diseases.
- Chest scans. CT scans of the chest are useful in distinguishing tumors and in detailing accumulation of fluid in chest infections.

Comment [2]: they are more comfortable for the patient and cheaper as well.

Comment [3]: part that is relevant to neurology

Comment [4]: minimally invasive medical test that uses x-rays and an iodine-containing contrast material to produce pictures of blood vessels in the brain. In cerebral angiography, a thin plastic tube called a catheter is inserted into an artery in the leg or arm through a small incision in the skin.

Comment [5]: can be used to detect brain aneurysm

Precautions

Pregnant women or those who could possibly be pregnant should not have a CT scan unless the diagnostic benefits outweigh the risks. Pregnant patients should particularly avoid full body or abdominal scans. If the exam is necessary for obstetrics purposes, technologists are instructed not to repeat films if there are errors. Pregnant patients receiving CT or any x-ray exam away from the abdominal area may be protected by a lead apron; most radiation, known as scatter, travels through the body and is not blocked by the apron.

Contrast agents are often used in CT exams and the use of these agents should be discussed with the medical professional prior to the procedure. Patients should be asked to sign a consent form concerning the administration of contrast. One of the common contrast agents, iodine, can cause allergic reactions. Patients who are known to be allergic to iodine (or shellfish) should inform the physician prior to the CT scan.

Comment [6]: the radiation can harm the baby

Comment [7]: make the changes more apparent, absorb external X-rays, resulting in decreased exposure on the X-ray detector.

Description

Computed tomography, also called CT scan, CAT scan, or computerized axial tomography, is a combination of focused x-ray beams and computerized production of an image. Introduced in the early 1970s, this radiologic procedure has advanced rapidly and is now widely used, sometimes in the place of standard x rays.

CT equipment

A CT scan may be performed in a hospital or outpatient imaging center. Although the equipment looks large and intimidating, it is very sophisticated and fairly comfortable. The patient is asked to lie on a gantry, or narrow table, that slides into the center of the scanner. The scanner looks like a doughnut and is round in the middle, which allows the x-ray beam to rotate around the patient. The scanner section may also be tilted slightly to allow for certain cross-sectional angles.

Comment [8]: the cross sectional angles are taken on both the x, y, z planes

CT procedure

The patient will feel the gantry move very slightly as the precise adjustments for each sectional image are made. A technologist watches the procedure from a window and views the images on a computer screen.

It is essential that the patient lie very still during the procedure to prevent motion blurring. In some studies, such as chest CTs, the patient will be asked to hold his or her breath during image capture. Following the procedure, films of the images are usually printed for the radiologist and referring physician to review. A radiologist can also interpret CT exams on a special computer screen. The procedure time will vary in length depending on the area being imaged. Average study times are from 30 to 60 minutes. Some patients may be concerned about claustrophobia, but the width of the "doughnut" portion of the scanner is such that many patients can be reassured of openness.

Comment [9]: patients with claustrophobia may not fare well...

The CT image

While traditional x rays image organs in two dimensions, with the possibility that organs in the front of the body are superimposed over those in the back, CT scans allow for a more three-dimensional effect. Some have compared CT images to slices in a loaf of bread. Precise sections of the body can be located and imaged as cross-sectional views. The screen before the technologist shows a

computer's analysis of each section detected by the x-ray beam. Thus, various densities of tissue can be easily distinguished.

Contrast agents

Contrast agents are often used in CT exams and in other radiology procedures to illuminate certain details of anatomy that may not be easily seen. Some contrasts are natural, such as air or water. Other times, a water-based contrast agent is administered for specific diagnostic purposes. Barium sulfate is commonly used in gastroenterology procedures. The patient may drink this contrast, or receive it in an enema. Oral and rectal contrast are usually given when examining the abdomen or cells, and not given when scanning the brain or chest. Iodine is the most widely used intravenous contrast agent and is given through an intravenous needle.

Comment [10]: used most commonly for the brain

If contrast agents are used in the CT exam, these will be administered several minutes before the study begins. Abdominal CT patients may be asked to drink a contrast medium. Some patients may experience a salty taste, flushing of the face, warmth or slight nausea, or hives from an intravenous contrast injection. Technologists and radiologists have equipment and training to help patients through these minor reactions and to handle more severe reactions. Severe reactions to contrast are rare, but do occur.

Comment [11]: check for allergies or ask about the experience beforehand

Spiral CT

Spiral CT, also called helical CT, is a newer version of CT scanning which is continuous in motion and allows for three-dimensional recreation of images. For example, traditional CT allows the technologist to take slices at very small and precise intervals one after the other. Spiral CT allows for a continuous flow of images, without stopping the scanner to move to the next image slice. A major advantage of spiral CT is the ability to reconstruct images anywhere along the length of the study area. The procedure also speeds up the imaging process, meaning less time for the patient to lie still. The ability to image contrast more rapidly after it is injected, when it is at its highest level, is another advantage of spiral CT's high speed.

Comment [12]: a continuous flow of images is more accurate, and it allows for the images to be easily interpreted by the laymen

Some facilities will have both spiral and conventional CT available. Although spiral is more advantageous for many applications, conventional CT is still a superior and precise method for imaging many tissues and structures. The physician will evaluate which type of CT works best for the specific exam purpose.

Preparation

If a contrast medium is administered, the patient may be asked to fast about four to six hours prior to the procedure. Patients will usually be given a gown (like a typical hospital gown) to be worn during the procedure. All metal and jewelry should be removed to avoid artifacts on the film.

Aftercare

No aftercare is generally required following a CT scan. Immediately following the exam, the technologist will continue to watch the patient for possible adverse contrast reactions. Patients are instructed to advise the technologist of any symptoms, particularly respiratory difficulty. The site of contrast injection will be bandaged and may feel tender following the exam. Hives may develop later and usually do not require treatment.

Risks

Radiation exposure from a CT scan is similar to, though higher than, that of a conventional x ray. Although this is a risk to pregnant women, the exposure to other adults is minimal and should produce no effects. Although severe contrast reactions are rare, they are a risk of many CT procedures.

Results

Normal findings on a CT exam show bone, the most dense tissue, as white areas. Tissues and fat will show as various shades of gray, and fluids will be gray or black. Air will also look black. Intravenous, oral, and rectal contrast appear as white areas. The radiologist can determine if tissues and organs appear normal by the sensitivity of the gray shadows. In CT, the images that can cut through a section of tissue or organ provide three-dimensional viewing for the radiologist and referring physician.

Comment [13]: contrast is white

Abnormal results

Abnormal results may show different characteristics of tissues within organs. Accumulations of blood or other fluids where they do not belong may be detected. Radiologists can differentiate among types of tumors throughout the body by viewing details of their makeup.

Comment [14]: can show a hemorrhage

Sinus studies

The increasing availability and lowered cost of CT scanning has led to its increased use in sinus studies, either as a replacement for a sinus x ray or as a follow-up to an abnormal sinus radiograph. The sensitivity of CT allows for location of areas of sinus infection, particularly chronic infection. CT scans can show the extent and location of tiny fractures to the sinus and nasal bones. Foreign bodies in the sinus and nasal area are also easily detected by CT. CT imaging of the sinuses is important in evaluating trauma or disease of the sphenoid bone (the wedge shaped bone at the base of the skull). Sinus tumors will show as shades of gray indicating the difference in their density from that of normal tissues in the area.

Sidebar: Hide

Key Terms

Aneurysm

The bulging of the blood vessel wall. Aortic aneurysms are the most dangerous. Aneurysms can break and cause bleeding.

Contrast (agent, medium)

A substance injected into the body that illuminates certain structures that would otherwise be hard to see on the radiograph (film).

Gantry

A name for the couch or table used in a CT scan. The patient lies on the gantry while it slides into the x-ray scanner portion.

Hematoma

A collection of blood that has escaped from the vessels. It may clot and harden, causing pain to the patient.

Hydrocephalus

A collection of fluid on or around the brain. The pressure from the spinal fluid causes the ventricles to widen.

Metastasis

Secondary cancer, or cancer that has spread from one body organ or tissue to another.

Radiologist

A medical doctor specially trained in radiology (x ray) interpretation and its use in the diagnosis of disease and injury.

Spiral CT

Also referred to as helical CT, this method allows for continuous 360-degree x-ray image capture.

Thoracic

Refers to the chest area. The thorax runs between the abdomen and neck and is encased in the ribs.

Brain studies

The precise differences in density allowed by CT scan can clearly show tumors, strokes, or lesions in the brain area as altered densities. These lighter or darker areas on the image may indicate a tumor or hematoma within the brain and skull area. Different types of tumors can be identified by the presence of edema, by the tissue's density, or by studying blood vessel location and activity. The speed and convenience of CT often allows for detection of hemorrhage before symptoms even occur. Congenital abnormalities in children, such as hydrocephalus, may also be confirmed with CT. Hydrocephalus is suggested by enlargement of the fluid structures called ventricles of the brain.

Comment [15]: excess of watery fluid

Body scans

The body scan can identify abnormal body structures and organs. Throughout the body, a CT may indicate tumors or cysts, enlarged lymph nodes, abnormal collections of fluids, blood or fat, and metastasis of cancer. Tumors resulting from metastasis are different in makeup than primary tumors, or those that originate in the location of study. Fractures or damage to soft tissues and ligaments will be more easily seen on the sensitive images produced by CT scanning, though CT is not usually done for these. Liver conditions, such as cirrhosis or abscessed or fatty liver, may be observed on the body scan.

CT of the aorta

CT provides the ability to see and measure the thickness of the aortal wall, which is very helpful in diagnosing aortic aneurysms. The use of contrast will help see details within the aorta. In addition, density can identify calcification, and this helps differentiate between acute and chronic problems. An abnormal CT scan may indicate signs of aortic clots. Aortic rupture is suggested by signs such as a hematoma around the aorta or the escape of blood from its cavity.

Comment [16]: can help with preventing because the thickness can be seen and recorded

Chest scans

In addition to those findings that may indicate aortic aneurysms, chest CT studies can show other problems in the heart and lungs, and distinguish between an aortic aneurysm and a tumor adjacent to the aorta. The computer will not only show differences between air, water, tissues, and bone, but will also assign numerical values to the various densities. Coin-sized lesions in the lungs may be indicative of tuberculosis or tumors. CT will help distinguish among the two. Enlarged lymph nodes in the chest area may indicate Hodgkin's disease. Spiral CT is particularly effective at identifying pulmonary emboli (clots in the lung's blood vessels).

Comment [17]: one way in which spiral CT scans are superior

Odle, Teresa. "Computed tomography scans." *The Gale Encyclopedia of Medicine*, edited by Jacqueline L. Longe, 5th ed., Gale, 2015. *Science In Context*, http://link.galegroup.com/apps/doc/EDABJA733175019/SCIC?u=j043905010&sid=SCIC&xid=88dc63ac. Accessed 4 Dec. 2018.

Head CT Interpretation

Video #1

* measurements taken in Hounsfield units (Hu) → relative density of a substance

↓ different windows

use to determine what is what on image

- air → -1000 Hu
- fat → -50 Hu
- water → 0 Hu
- blood 30-45 Hu
- muscle → 40 Hu
- bone 1000 Hu

* alter the Hu range/gradient to show | bone structure / soft tissue detail
* important to look at windows (ALL)

Blood	B	1) blood
can	C	2) cisterns
Be	B	3) brain
very	V	4) ventricles
Bad	B	5) bone

what to look for and in what order

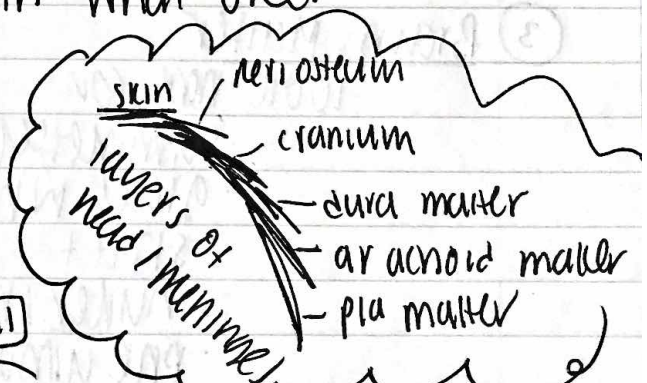

① **Blood**

- bright white on CT
- 5 types

dura (skull)

lens-shaped · EDH epidural hematoma (tear in artery) between

sickle-shaped esp basal ganglia · SDH subdural hematoma (blood gathers in inner layer of dura & arachnoid matter)

hyperacute · intra parenchymal (bleeding in parenchyma → functional brain tissue (cells, neurons, glial cells))

· intraventricular (bleeding in ventricles)

subarachnoid hemorrhage · SAH (bleeding in subarachnoid space.. where CSF is) aka cisterns

big ventricular not good ... hydrocephalus
mass effect = growing mass that
results in secondary path effects

14:13

in EDH... can see ventricles collapsed a bit.. shift of midline

acute blood: bright white blood ... clots
↓
breaks down
↓
leaked back in middle

circle of willis
· supplies blood to the brain
in the middle

look at pic

② Cisterns
· fluid (space containing fluid)
· 4 types
1) circummesencephalic (ring around midbrain)
2) supra sellar (star-shaped) circle of willis
3) quadrigeminal (W-shaped)
4) sylvian (between frontal & temporal lobes)

W or
at sides

③ Brain Matter
· look for
· symmetry →
· gray-white differentiation
· shift
· hyper/hypodensity (compared to reference area) (hyper = bright white) (hypo = black)
· pneumocephalus